

A 51-Year-Old Woman with Right Dorsal Foot Pain

Sheng-Hao Cheng, Tyng-Guey Wang*

Department of Physical Medicine and Rehabilitation, National Taiwan University Hospital and National Taiwan University College of Medicine, Taipei, Taiwan

SECTION 2 – ANSWER

A 51-year-old woman had insidious painful sensation over her right dorsal foot. The pain aggravated in walking. Physical examination showed mild swelling of the right dorsal foot without concurrent erythema or local heat but exaggerative pain when squeeze tests were performed. The Tinel's sign at the right dorsal foot was negative. The following ultrasound images showed the transverse and longitudinal views of the right dorsal foot [Figure 1].

Interpretation

There was a homogeneous hypoechoic lesion between the third and the fourth metatarsal bones located at the plantar site of the foot without obvious posterior enhancement. The lesion has no vascularity in the result of Doppler sonography and with less compressibility. However, in the follow-up sonography, we found several septa within the mass and obvious posterior enhancement, indicating a possible homogeneous fluid substance rather than a solid mass [Figure 1a], and magnetic resonance imaging (MRI) study also showed the same pathology [Figure 1b].

DISCUSSION

Ganglion cysts are the most common benign soft tissue tumor. It usually contains mucinous material and develops along tendon sheath and joint capsule around the wrist, hand, knee, and foot.^[1] Ganglion cysts are mostly asymptomatic, but it can cause pain and local lumps in some occasions.^[2] Ganglion cysts represent 42% of clinically suspected soft tissue masses in the foot and are found most commonly in tarsal tunnel, sinus tarsi, and Lisfranc joint.^[3] Previous retrospective study also reports that ganglion cysts are commonly found in the dorsal aspect of the foot.^[4]

Although ganglion cysts are common findings among the soft tissue tumors in the foot, other possible diagnoses should also be taken into consideration, including bursitis, synovial cysts,

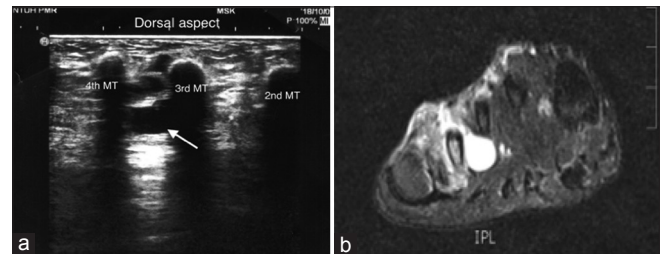


Figure 1: (a) Follow-up ultrasound images showing the transverse view of the right dorsal foot. (b) Magnetic resonance imaging T2-weighted image of the right dorsal foot, coronal view. (MT: Metatarsal bone, Arrow: The lesion)

Morton's neuromas, and even arthritis. The ganglion cysts in the MRI image are well-defined round or multilobulated with high T2 signal and smooth border and usually close to joints or tendon.^[3] Compared with ganglion cysts, a bursitis usually occurs in some characteristic locations, such as intermetatarsal, retrocalcaneal, retro-Achilles, forefoot, or malleolar bursae.^[3] Morton's neuromas usually occur in the second or the third intermetatarsal space, along the plantar aspect of the transverse intermetatarsal ligament, featuring isointensity to muscles on T1 image due to fibrosis.

The classical sonographic feature of the ganglion cyst is anechoic with acoustic enhancement deep to the cyst. However, the viscous nature of the content may create echogenicity within the cyst. The ganglion cyst was less compressible than synovial cyst and bursa under ultrasonography due to its thick and vicious contents.^[1-5] Sonographic-guided aspiration with a large gauge needle may help in making diagnosis and can be a part of conservative treatment.^[6] Different from ganglion cysts or synovial cysts, Morton's neuromas should be uncompressible and may reproduce symptoms related to the neuromas during compression by the probe.^[7] Sonographic

Address for correspondence: Dr. Tyng-Guey Wang,
Department of Physical Medicine and Rehabilitation, College of Medicine,
National Taiwan University Hospital, National Taiwan University, Taipei,
Taiwan.
E-mail: tgw@ntu.edu.tw

Received: 12-11-2018 Accepted: 25-12-2018 Available Online: 04-06-2019

Access this article online

Quick Response Code:



Website:
www.jmuonline.org

DOI:
10.4103/JMU.JMU_110_18

This is an open access journal, and articles are distributed under the terms of the Creative Commons Attribution-NonCommercial-ShareAlike 4.0 License, which allows others to remix, tweak, and build upon the work non-commercially, as long as appropriate credit is given and the new creations are licensed under the identical terms.

For reprints contact: reprints@medknow.com

How to cite this article: Cheng SH, Wang TG. A 51-year-old woman with right dorsal foot pain. J Med Ultrasound 2019;27:162-3.

Mulder's test, improving visualization of the lesion via increased interdigital pressure at the level of metatarsal head, may increase the diagnostic accuracy.^[8]

In this case, the lesion was hypoechoic and homogeneous with no vascularity and less compressibility under sonographic image, which was compatible with the characteristics of a ganglion cyst. Posterior enhancement was not apparently shown in the initial sonographic exam, but was apparently shown in the follow-up one, which is helpful for diagnosis. The MRI image revealed an elongated cystic lesion with increased periosteal and bone marrow signal in the T2-weighted image [Figure 1b]. The sonographic and the MRI diagnoses of the lesion indicate a ganglion cyst. We had done ultrasound-guided corticosteroid injection with a 23-gauge needle, and the pain over the dorsal aspect of the right foot was gradually relieved after the injection. The procedure did not cause Tinel's sign, which indicated that the lesion was not a neurogenic tumor. Although the ganglion cyst usually could be aspirated, the mucinous content of the cyst failed to be aspirated through the small-gauge needle in this case.

This case exemplifies ultrasonography as a useful tool for diagnosis of a foot lump and suggests that ultrasound-guided intervention may be an effective management of ganglion cysts to patients who are not indicated to surgical intervention.

Financial support and sponsorship

Nil.

Conflicts of interest

There are no conflicts of interest.

REFERENCES

1. Giard MC, Pineda C. Ganglion cyst versus synovial cyst? Ultrasound characteristics through a review of the literature. *Rheumatol Int* 2015;35:597-605.
2. Brukner P, Clarsen B, Cook J, Cools A, Crossley K, Hutchinson M, *et al.* Brukner & Khan's Clinical Sports Medicine: Injuries, Vol. 1. 5th ed. Australia: McGraw-Hill Education; 2017.
3. Hochman MG, Wu JS. MR imaging of common soft tissue masses in the foot and ankle. *Magn Reson Imaging Clin N Am* 2017;25:159-81.
4. Giard MC, Pineda C. Ganglion cyst versus synovial cyst? Ultrasound characteristics through a review of the literature. *Rheumatol Int* 2015;35:597-605.
5. Ruangchaijatuporn T, Gaetke-Udager K, Jacobson JA, Yablon CM, Morag Y. Ultrasound evaluation of bursae: Anatomy and pathological appearances. *Skeletal Radiol* 2017;46:445-62.
6. Ju BL, Weber KL, Khoury V. Ultrasound-guided therapy for knee and foot ganglion cysts. *J Foot Ankle Surg* 2017;56:153-7.
7. Jacobson JA. *Fundamentals of Musculoskeletal Ultrasound*. 3rd ed. Philadelphia: Elsevier Health Sciences; 2017.
8. Torriani M, Kattapuram SV. Technical innovation. Dynamic sonography of the forefoot: The sonographic mulder sign. *AJR Am J Roentgenol* 2003;180:1121-3.